

## ORIGINAL ARTICLE

# Cutaneous eruption in COVID-19-infected patients in Thailand: An observational descriptive study

Preawphan PUNYARATABANDHU,  Pornchai CHIRACHANAKUL*Department of Disease Control, Ministry of Public Health, Bamrasnaradura Infectious Diseases Institute, Nonthaburi, Thailand***ABSTRACT**

Coronavirus disease 2019 (COVID-19) emerged in Thailand in January 2020. Thailand was the first to report a confirmed case outside China. Cutaneous eruption in COVID-19 has been reported since the disease became pandemic but limited in tropical countries such as Thailand. The aim of this study was to observe the incidence, characteristics and relation of cutaneous eruption with COVID-19 at Bamrasnaradura Infectious Diseases Institute, a referral center of emerging infectious diseases in Thailand. An observational descriptive study observed the incidence and characteristics of cutaneous eruption in 204 COVID-19-infected patients at Bamrasnaradura Infectious Diseases Institute. We report five patients, who represented six incidences of skin eruption with four characteristics: maculopapular rash (50%), acute generalized exanthematous pustulosis (16.67%), Stevens–Johnson syndrome (16.67%) and urticarial vasculitis (16.67%). Incidences of cutaneous eruption in COVID-19 at Bamrasnaradura Infectious Diseases Institute were low. Most of the incidents were associated with medication used to treat COVID-19 infection, so drug allergy cannot be excluded as a cause of the rashes. Therefore, drug allergy should always be ruled out, and skin manifestation in COVID-19-infected patients should be further observed.

**Key words:** corona virus, COVID-19, cutaneous eruption, drug eruption, skin manifestation.

**INTRODUCTION**

Coronavirus disease 2019 (COVID-19) is highly contagious and is still spreading rapidly. The pathogen causing this transmissible disease is severe acute respiratory syndrome coronavirus 2 (SARS-CoV-2), and it is diagnosed by real-time reverse transcription polymerase chain reaction (RT-PCR) assay for SARS-CoV-2 RNA. COVID-19 is transmitted primarily by respiratory droplets and close contact. The incubation or asymptomatic period of the disease is 14–21 days.<sup>1</sup> COVID-19 was announced as a pandemic in March 2020 by the World Health Organization. However, this communicable disease had already emerged in Thailand in January 2020, and the country was the first to report a COVID-19-infected patient outside of China. Bamrasnaradura Infectious Diseases Institute (BIDI) is a referral center of emerging infectious diseases (EID) in Thailand, and BIDI responded to the first confirmed case in Thailand. At BIDI, all suspected COVID-19 cases receive a diagnostic test by RT-PCR. Suspected COVID-19 cases are defined by Thai national surveillance guidelines<sup>2</sup> as patients with a body temperature of more than 37.5°C, any respiratory symptom and risk of infection defined as contact with a confirmed case, attending a crowded place that had a confirmed case or traveling from a country with widespread transmission of COVID-19. All cases

diagnosed as confirmed COVID-19 infection are hospitalized and are treated following the Thai guidelines for treatment of COVID-19 categorized according to clinical sign, severity and risk factor. Antimalarial and antiretroviral drugs are currently the mainstay of treatment, but in severe cases antimicrobial or immunological drugs are considered.<sup>2</sup> There have been reports of skin manifestations in COVID-19-infected patients since the end of March 2020. These reported manifestations include urticarial rash, erythematous rash, vesicle, livedo reticularis and pemphigus. However, most of the reported cases came from Western countries, such as in Europe and the USA.<sup>3–9</sup> There are few reports from Asia.<sup>10,11</sup> Therefore, we herein describe the incidence and characteristics of cutaneous eruptions, and their relation to COVID-19 infection during the emerging period of COVID-19 in Thailand.

**METHODS**

This study is an observational descriptive study of confirmed COVID-19-infected patients with cutaneous eruption presenting at BIDI from 8 January 2020 to 31 May 2020. The inclusion criteria were: (i) a confirmed COVID-19-infected patient diagnosed by RT-PCR for SARS-CoV-2 from a nasopharyngeal and/or throat swab; and (ii) the presence of a cutaneous

Correspondence: Preawphan Punyaratabandhu, M.D., Bamrasnaradura Infectious Diseases Institute, Department of Disease Control, Ministry of Public Health, 38 Soi Tiwanon 14, Tiwanon Road, Nonthaburi 11000, Thailand. Email: preawphan.p@gmail.com  
 Received 17 June 2020; revised 18 August 2020; accepted 28 August 2020.

eruption during the diagnosis and treatment of the COVID-19 infection, as well as during collecting the data until 31 May 2020. Exclusion criteria was any documented skin rash that developed 2 weeks prior to the diagnosis of the COVID-19 infection according to incubation period. The severity of patients with COVID-19 was categorized into two groups, namely those who developed pneumonia (severe group) and those who had mild symptoms (mild group). Cutaneous eruption was defined as skin, nail, hair or mucocutaneous disease. We collected the clinical data of enrolled COVID-19-infected patients from the medical records at BIDI. This study was approved by the BIDI institutional review board (ID S016h/63\_ExPD), and all patients who were enrolled in the study gave their informed consent. The study was performed in accordance with the Declaration of Helsinki.

## RESULTS

Of the 204 COVID-19-infected patients who were hospitalized at BIDI, cutaneous eruption was found in five (2.45%). One of these patients developed two separate episodes of skin rash during the COVID-19 infection. Including the two episodes described above, there were six incidences of skin eruption in COVID-19-infected patients. All cases were diagnosed by a dermatologist. The five cases are presented in Table 1.

### Case 1

A 48-year-old Thai man presented with fever and headache for 4 days, and was diagnosed with COVID-19 infection. He was treated with chloroquine (CQ) and lopinavir/ritonavir (LPV/r). After 11 days of positive RT-PCR testing and 9 days after starting medications, he developed an itchy rash on the truncal area, which then progressed to the facial area with small pustules. His face became swollen. At that time, he developed a fever but did not have any respiratory symptoms. Physical examination showed multiple non-follicular minute pustules on an edematous erythematous base on the face, trunk and in both axillae (Fig. 1a). Complete blood count showed leukocytosis with neutrophil predominance without eosinophilia. His skin biopsy showed subcorneal pustules in the epidermis as well as superficial and mid-dermal infiltration with lymphohistiocytes and eosinophils. This case was diagnosed as acute generalized exanthematous pustulosis (AGEP). The diagnostic score for AGEP from the AGEP validation score of the EuroSCAR study group was 10 (morphology, 6; course, 2; histology, 2), which is classified as definitive AGEP.<sup>12</sup> At that time, the possibility of drug allergy could not be excluded, with either CQ and LPV/r as possible culprit agents. Both medications were discontinued, and systemic and topical corticosteroids were prescribed. The fever and pustules were resolved, and desquamation was found with postinflammatory hyperpigmentation (PIH) 2 days after discontinuation of the suspected culprit agents. The rash occurred while RT-PCR for SARS-CoV-2 was positive. RT-PCR was repeated and was reported as undetectable for SARS-CoV-2 10 days after the onset of the rash.

### Case 2

A 38-year-old Thai woman presented with fever and dry cough for 1 day and was diagnosed with COVID-19 infection with pneumonia. She was treated with CQ, favipiravir (FVP), darunavir (DRV), ritonavir (RTV) and antibiotic (ceftriaxone). Twelve days after diagnosis of COVID-19, her clinical condition improved, and her RT-PCR for SARS-CoV-2 was undetectable. Most medications were discontinued, but she was prescribed cefixime to complete her course of antibiotic. Five days after the undetectable RT-PCR and 4 days after starting cefixime, an itchy and painful rash developed on her trunk, which then progressed to her face and extremities with a painful lesion in her mouth (Fig. 1b). She was diagnosed with Steven-Johnson syndrome (SJS) because her physical examination showed erosion on both lips and oral mucosa, injected conjunctiva, non-blanchable red to dusky red macules and papules on the face and trunk, as well as purpuric patches on both of the hands and feet. Nikolsky's sign was positive on the lesion on her back, but skin detachment was less than 5%. Because SJS is one of the severe cutaneous adverse drug reactions (SCAR), and drug allergy could not be excluded, the suspected culprit agent was discontinued immediately. Her laboratory tests showed neither eosinophilia nor transaminitis. She was treated with systemic and topical corticosteroids. Her rash improved after termination of the suspected offending agent within 4 days and became PIH.

### Case 3

A 53-year-old Thai woman was diagnosed COVID-19 infection with pneumonia after developing fever, cough and muscle pain for 8 days. She was treated with multiple agents including FPV, LPV/r, hydroxychloroquine (HCQ), azithromycin, meropenem and tocilizumab. After 9 days of positive RT-PCR and 8 days after starting medications, she developed an itchy rash on her trunk and extremities. Physical examination showed a maculopapular (MP) rash on the truncal area and extremities without mucosal involvement, fever or lymphadenopathy (Fig. 1c,d). Her laboratory data showed no eosinophilia but her liver function test showed transaminitis. After 10 days of medications, all drugs were discontinued and only a topical corticosteroid was prescribed. Her skin lesions became subtle with PIH, and the itch disappeared within 5 days. The rash occurred while RT-PCR was still positive for SARS-CoV-2, but repeated RT-PCR reported undetectable for SARS-CoV-2 at 6 days after the onset of the rash.

### Case 4

A 22-year-old Thai woman presented with fever and dyspnea for 2 days and then was diagnosed COVID-19 infection. She was treated with CQ and LPV/r. After 10 days of positive RT-PCR and 8 days of using the medications, she developed an itchy rash on her extremities, which spread to her truncal area. She was afebrile and physical examination showed non-blanchable red plaque on her face, trunk and extremities with neither mucosal involvement nor lymphadenopathy (Fig. 1e,f). From the clinical presentation, the dermatologist diagnosed urticarial vasculitis. The laboratory showed neither

**Table 1.** Summary of five cases

	Case 1	Case 2	Case 3	Case 4	Case 5
No. of episodes of rash	1	1	1	1	2
Age (years)	48	38	53	22	49
Sex	Male	Female	Female	Female	Female
Severity of COVID-19	Mild	Severe	Severe	Mild	Severe
Presenting symptom of COVID-19	Fever Headache	Fever Cough	Fever Cough Muscle pain	Fever Dyspnea	Fever Cough
Risk of transmission	Contact-confirmed COVID-19 case	Attended a crowded place	Traveled from a country with widespread transmission of COVID-19	Contact-confirmed COVID-19 case	Attended a crowded place
Underlying disease	None	None	None	None	None
Medication before COVID-19 infection	None	None	None	None	None
History of drug allergy	None	None	None	None	None
Underlying skin condition	None	None	None	None	None
Family history of skin disease	None	None	None	None	None
Duration from positive to negative RT-PCR for SARS-CoV-2 (days)	20	12	14	12	18
Medication during treatment of COVID-19	CQ, LPV/r	CQ, DRV, RTV, FVP, ceftriaxone, cefixime	HCQ, LPV/r, FVP, azithromycin, ceftriaxone, meropenem, tocilizumab	CQ, LPV/r	CQ, DRV, RTV, FVP, azithromycin, ertapenem

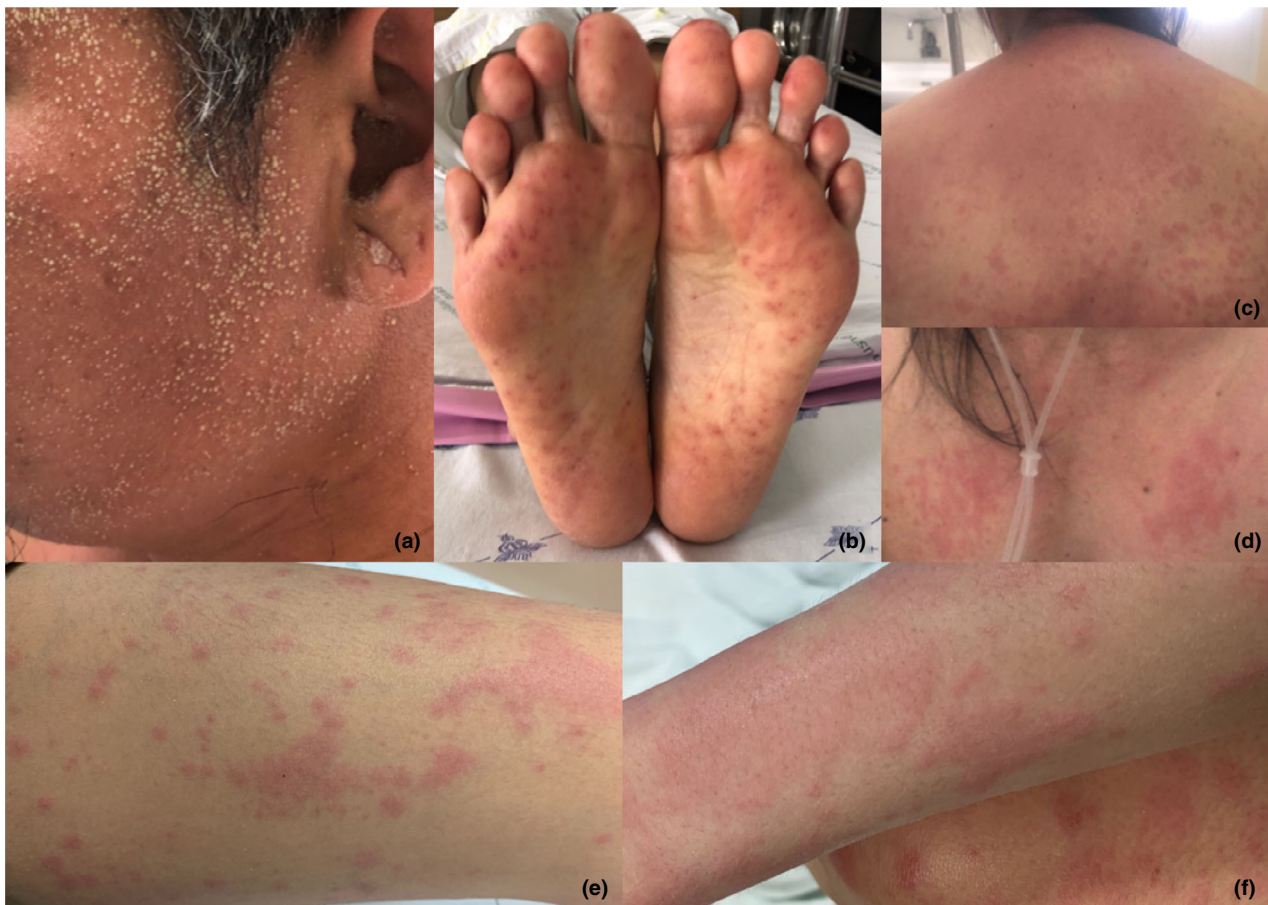	Episode 1	Episode 2
Characteristic of rash	AGEP	SJS
Symptom of rash	Itch	Pain, itch
Time to rash since diagnosis of COVID-19 (days)	11	17
Duration of rash (days)	5	4
Systemic symptom during rash occurrence	Fever	Fever
Laboratory†	Leukocytosis, neutrophilia	Found Atyp L
Consequence of the rash	Desquamation, PIH	PIH
Positive RT-PCR for SARS-CoV-2 during rash occurrence	Yes	No
Skin biopsy	Yes	No
Treatment	Systemic and topical corticosteroid, antihistamine	Systemic and topical corticosteroid, antihistamine

†Complete blood count, serum creatinine, urinary analysis and liver function test were done in every case on the day of developing rash; only abnormal results shown. AGEP, acute generalized exanthematous pustulosis; Atyp L, atypical lymphocyte; CQ, chloroquine; DRV, darunavir; FVP, favipiravir; HCQ, hydroxychloroquine; LPV/r, lopinavir/ritonavir; MP rash, maculopapular rash; PIH, postinflammatory hyperpigmentation; RT-PCR, reverse transcription polymerase chain reaction; RTV, ritonavir; SJS, Stevens–Johnson syndrome.

eosinophilia nor transaminitis. Skin biopsy was done, and the report showed edema of the upper dermis as well as superficial and mid-dermal infiltration with lymphocytes, eosinophils

and neutrophils. Also, the slide showed many neutrophils in the lumen of dilated blood vessels, but there was neither vasculitis nor thrombosis in the histopathology.



**Figure 1.** Clinical pictures of skin rash of cases 1–4. (a) Non-follicular minute pustules of case 1. (b) Purpuric macules on both feet of case 2. (c) Maculopapular rash on back of case 3. (d) Maculopapular rash on chest wall of case 3. (e) Non-blanchable red papules and plaques on leg of case 4. (f) Partially blanchable red plaques on forearm of case 4.

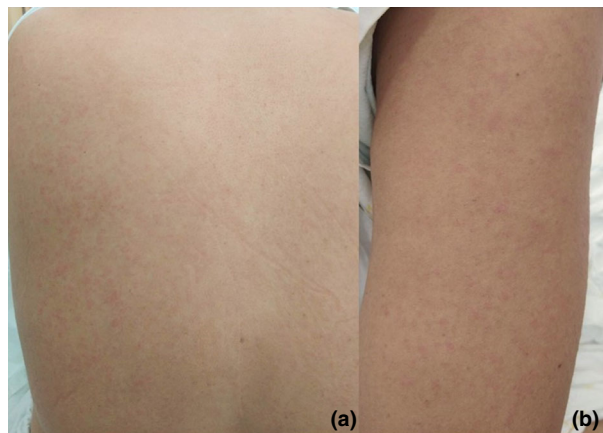
Immunohistochemistry (IHC) was done but failed to demonstrate significant deposition of immunoglobulin (Ig)G, IgM and IgA around the vessel wall when compared with a control. At that time, drug allergy could not be excluded. Therefore, the possible offending agents, including CQ and LPV/r, were discontinued and she was treated with a topical corticosteroid. The rash resolved with PIH 3 days after discontinuation of the medications.

#### Case 5

A 49-year-old Thai woman presented with fever and dry cough for 5 days before positive RT-PCR for SARS-CoV-2. She was treated with multiple agents due to pneumonia including DRV, RTV, CQ, FVP, azithromycin and ertapenem. After 15 days of positive RT-PCR, she developed an itchy rash and fever. There was an MP rash on her truncal area and extremities without mucosal lesion. No superficial lymph nodes were enlarged. The absolute eosinophil count was  $135 \text{ cells/mm}^3$ , and the liver function test showed transaminitis. All

medications were discontinued. She was treated with systemic and topical corticosteroids and her rash resolved within 4 days. RT-PCR for SARS-CoV-2 was repeated and was reported as undetected on day 18 of the admission. After 2 days of undetectable RT-PCR for SARS-CoV-2, she noticed a new rash on her truncal area that spread to her extremities, without fever or itching. The physical examination showed an MP rash on her truncal area without mucosal involvement (Fig. 2). There were no new medications. Her laboratory tests were repeated. There was no eosinophilia, and her liver function test was improved. This second episode of rash was treated with a topical corticosteroid and resolved within 7 days without PIH. The timeline of the two episodes of rashes are shown in Figure 3.

Summarizing the five cases of patients with COVID-19 and skin rash, four were female, and only one of the five cases was not infected via local transmission. The mean  $\pm$  standard deviation [SD] age was  $42 \pm 12.47$  years. Three of the five cases had severe COVID-19, but none were non-survivors. All five

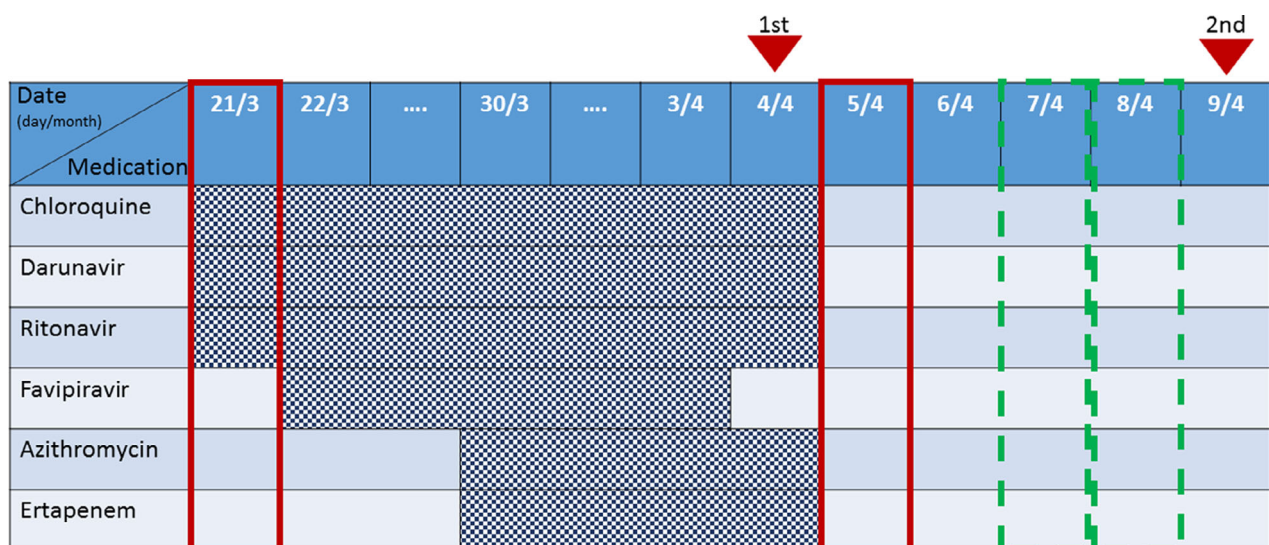


**Figure 2.** Maculopapular rash of case 5, second episode. Lesions on (a) back (b) and arm.

cases developed skin lesions after diagnosis of COVID-19 infection. The mean  $\pm$  SD duration between diagnosis of COVID-19 and rash occurrence was  $13.67 \pm 4.37$  days, and the mean  $\pm$  SD duration of the rash was  $5.00 \pm 1.67$  days. Five of the six incidences of skin eruption developed while new medications were prescribed during the treatment of COVID-19. Only one of the six incidences of rash occurred after all medications were discontinued. Cutaneous eruption in all five cases were diagnosed by a dermatologist. Of the six incidences of rash, three were MP rashes, one AGEP, one SJS and one urticarial vasculitis.

## DISCUSSION

Five of the 204 cases (2.45%) of COVID-19 patients treated at BIDI during 8 January to 31 May 2020 developed cutaneous eruption. To the best of our knowledge, few studies of cutaneous lesions associated with COVID-19 in Asians have been reported, and are especially rare in tropical countries such as Thailand. The incidence of cutaneous eruption in our study was low compared with a previous Italian study that reported 20.4% of COVID-19 cases had a skin manifestation.<sup>3</sup> However, the incidence may be lower amongst Asian patients with COVID-19 with a study from China reporting only 0.2% of cases having a rash.<sup>11</sup> The low incidence may be possibly due to many factors, such as the race and genetics of infected patients. However, the incidence of cutaneous eruption in Asia should be further observed and investigated to gain more information. The low incidence of cutaneous eruption in the present study could possibly be influenced by many factors. The study was an observational study and retrieved all information from medical records, so the data may be incomplete. The study was done in a short period of time; therefore, a late-onset cutaneous eruption among COVID-19-infected patients could possibly be missing. Moreover, most Thai patients tend to have a darker skin type when compared with Caucasian, Fitzpatrick skin type 4–5, which may cause more difficulty in diagnosis because the color of the skin may mask the lesion, leading to underdiagnosis. It was notable that a previous report described that skin lesions associated with COVID-19 infection were not itchy or had only mild symptoms,<sup>3</sup> which may be less noticeable to the patients. Therefore, the dermatologist may need to look more carefully for a skin lesion in darker-skinned individuals infected with COVID-19.



**Figure 3.** Timeline of two episodes of rashes in case 5, and the relationship with medications. Real-time reverse transcription polymerase chain reaction (RT-PCR) for SARS-CoV-2 RNA. Red lined boxes refer to a day of positive RT-PCR; green dashed line boxes refer to a day of negative RT-PCR; red triangles indicate the day rash developed; checkered boxes indicate exposure time of each medication.

In the present study, we found a major characteristic of the rash was MP rash, which is also similar to previous reports.<sup>3,8</sup> There was a series of cases reporting hypercoagulability and skin necrosis from China,<sup>10</sup> and we also found purpuric macules and plaques on both of the hands and feet in one of our cases. However, our patient was diagnosed with SJS. We found no patient with livedo reticularis or perniois as reported in the USA and Europe.<sup>4,5</sup> This discordance with our finding might have been due to the warmer climate in Thailand and/or genetic predisposition as a report from Spain identified a familial cluster of perniois.<sup>8</sup>

There have been reports about hypercoagulable state and vasculopathy in COVID-19.<sup>9,10</sup> We performed a skin biopsy in two of six incidences of rash in the present study while the patients were still RT-PCR-positive for SARS-CoV-2, but no histology of vasculopathy or vasculitis was seen. We found one case diagnosed with urticarial vasculitis from the clinical presentation as urticarial rash that lasted for more than 24 h, and the rash resolved with PIH. Nevertheless, the skin biopsy did not show vasculitis in the histopathology as there was no nuclear dust and no fibrinoid necrosis of the blood vessel. Direct immunofluorescence was not done to confirm vasculitis in tissue due to the risk that the procedure could have transmitted SARS-CoV-2 virus. IHC was done, but failed to demonstrate significant deposition of IgG, IgM and IgA around vessel walls when compared with a control. It showed a negative result, which was possible because the biopsy was done in an early lesion.

In the present study, all incidences of rash occurred after the patients were diagnosed with COVID-19. We did not find skin eruption prior to their diagnosis of COVID-19 infection as in previous reports.<sup>7</sup> Five incidences of rash in our study were associated with medications used to treat COVID-19 infection, so drug allergy cannot be excluded as a cause of the rashes that were itchy and resolved after discontinuation of medication. However, we could not definitely conclude that the rashes were drug-related. The dermatologist diagnosed based on clinical and laboratory tests. To confirm a drug reaction, a positive drug provocation test or oral rechallenge with the suspected offending agent would have been needed. If the patient had not developed a rash after rechallenge with the suspected agent, COVID-19 infection would have been assumed to be the most likely causative exposure. However, we found two incidences of rash that were AGEP and SJS, which are SCAR, so the rechallenge could have led to life-threatening reactions. Therefore, we did not perform rechallenge with suspected agents to confirm drug reaction.

In our experience at BIDI, as a referral center of infectious diseases, we have rarely found cutaneous adverse drug reactions from antimalarials or protease inhibitors, an antiretroviral drug. However, we observed two cases of suspected drug rash in which the possible offending agents were differentiated between those two groups of medication. Moreover, we found two incidences of rash that developed into SCAR (AGEP and SJS). These incidences of suspected drug eruption could have possibly arisen by using a combination of the medications or by immune activation from the COVID-19 disease. There was a

report of cytokine storm or hyperinflammation in COVID-19-infected patients.<sup>13</sup> Therefore, cytokine and inflammatory factors could have possibly played a role.

We found one incidence of an asymptomatic MP rash occurring after all medications were discontinued. This rash developed after the patient's clinical signs and symptoms were improved and RT-PCR was undetectable for SARS-CoV-2, and the rash resembled a convalescent rash. Therefore, the rash was suspected to be a skin manifestation of COVID-19. However, there was no clear-cut evidence that the rash was viral-induced. Skin biopsy is not a standard investigation for viral exanthem, which is normally diagnosed by clinical data and history of the disease.

The main limitation of the present study is the lack of laboratory tests and procedures that could have confirmed the causes of the skin eruption in these cases. This lack of objective evidence occurred due to the high risks of contagion and transmission, and risks to severely harm the patients by performing procedures such as drug provocation tests. Because COVID-19 is still an emerging infectious disease, the pathophysiology of the disease is still unclear. Therefore, any COVID-19-related, pathophysiological mechanism that causes rash to develop in patients with COVID-19 is unclear at this time. Further observations and laboratory research are still needed to study and confirm the association and mechanisms of skin rash seen in patients with COVID-19. Moreover, due to the low incidence of rash, data on skin manifestation in COVID-19 at our institute should be further collected to gain more insight into the relationship between rash and COVID-19. In our study, we found that drug allergy could not be excluded as a cause of most of the rashes, and this would be an iatrogenic cause, leading to morbidity and mortality. Therefore, we recommend that drug allergy should be ruled out before diagnosing rash as a skin manifestation in the COVID-19-infected patient receiving new medication.

**CONFLICT OF INTEREST:** None declared.

## REFERENCES

- 1 Han Y, Yang H, The transmission and diagnosis of 2019 novel coronavirus infection disease (COVID-19): A Chinese perspective. *J Med Virol* 2019; **2020**: 1–6.
- 2 Guidelines for clinical practice, diagnosis, treatment and prevention of healthcare-associated infection in response to patients with COVID-19 infection for medical and healthcare personnel prepared by Working Group on Medical Treatment and Prevention of Healthcare-Associated Infection, Department of Medical Services, Ministry of Public Health in collaboration with a panel of subject matter experts from local medical schools [Cited 2020 April 8] Available from: [https://ddc.moph.go.th/viralpneumonia/eng/file/guidelines/g\\_CPG.pdf](https://ddc.moph.go.th/viralpneumonia/eng/file/guidelines/g_CPG.pdf)
- 3 Recalcati S. Cutaneous manifestations in COVID-19: a first perspective. *J Eur Acad Dermatol Venereol* 2020; **34**: e212–e213. <https://doi.org/10.1111/jdv.16387>
- 4 Manalo IF, Smith MK, Cheeley J, Jacobs R. A dermatologic manifestation of COVID-19: transient livedo reticularis. *J Am Acad Dermatol* 2020; **83**: 700.

- 5 Kolivras A, Dehavay F, Delplace D, et al. Coronavirus (COVID-19) infection-induce chilblains: a case report with histopathologic findings. *JAAD Case Rep* 2020; **6**(6): 489–492. <https://doi.org/10.1016/j.jdc.2020.04.011>
- 6 Bouaziz JD, Duong T, Jachiet M et al. Vascular skin symptoms in COVID-19: a French observational study. *J Eur Acad Dermatol Venereol* 2020; **34**: e451–e452. <https://doi.org/10.1111/jdv.16544>
- 7 Van Damme C, Berlingin E, Saussez S, Accaputo O. Acute urticaria with pyrexia as the first manifestations of a COVID-19 infection. *J Eur Acad Dermatol Venereol* 2020; **34**: e300–e301. <https://doi.org/10.1111/jdv.16523>
- 8 Galván CC, Català A, Carretero HG et al. Classification of the cutaneous manifestations of COVID -19: a rapid prospective nationwide consensus study in Spain with 375 cases. *Br J Dermatol* 2020; **183** (1): 71–77. <https://doi.org/10.1111/bjd19163>
- 9 de Perosanz-Lobo D, Fernandez-Nieto D, Burgos-Blasco P et al. Urticarial vasculitis in COVID-19 infection: a vasculopathy-related symptom? *J Eur Acad Dermatol Venereol* 2020. <https://doi.org/10.1111/jdv.16713>
- 10 Zhang Y, Cao W, Xiao M et al. Clinical and coagulation characteristics of 7 patients with critical COVID-2019 pneumonia and acro-ischemia. *Zhonghua Xue Ye Xue Za Zhi* 2020; **41**: e006. <https://doi.org/10.3760/cma.j.issn.0253-2727.2020.0006>
- 11 Guan WJ, Ni ZY, Hu Y et al. Clinical characteristics of coronavirus disease 2019 in China. *N Engl J Med* 2020; **382**(18): 1708–1720.
- 12 Sidoroff A, Halevy S, Bavinck JN, Vaillant L, Roujeau JC. Acute generalized exanthematous pustulosis (AGEP) – a clinical reaction pattern. *J Cutan Pathol* 2001; **28**: 113–119.
- 13 Prompetchara E, Ketloy C, Palaga T. Immune responses in COVID-19 and potential vaccines: lessons learned from SARS and MERS epidemic. *Asian Pac J Allergy Immunol.* 2020; **38**(1): 1–9.